

## NON-INVASIVE ULTRASONOGRAPHIC DIAGNOSTICS OF Rh(D) ALLOIMMUNIZED PREGNANCIES

by

**Darko V. PLEČAŠ<sup>1</sup>, Monika M. ŽIVKOVIĆ<sup>2</sup>, and Svetlana M. PEJOVIĆ<sup>3</sup>**

<sup>1</sup>Institute for Gynaecology and Obstetrics, Clinical Centre of Serbia, Belgrade, Serbia

<sup>2</sup>Clinical Hospital Centre Zemun, Belgrade, Serbia

<sup>3</sup>State University of Novi Pazar, Novi Pazar, Serbia

Scientific paper

DOI: 10.2298/NTRP1201064P

A non-invasive ultrasonographic assessment of systolic ejection peak in the middle cerebral artery is very efficient in detection of anomalies in alloimmunized pregnancies and is a diagnostic method of choice prior to cordocentesis. This is applied in combination with detection of titre of Rh(D) antibodies. In our study, two groups of patients were tested and results were compared. The first sample included 52 newborns in the period 1998-2007 (initial period of intrauterine intravascular transfusion, while the second one included 16 newborns from the period 1998-2008 (second period, when better prenatal control was achieved). Levels of titer of antibodies in salty environment, in both the control and the analyzed group, indicated moderate sensitization in a small group of patients. However, in albumin and in particular Coombs environment, the level of sensitization was significant in all patients ( $p > 0.05$ ; DF = 67). Our investigation suggests that with ultrasound as a method of choice and with prenatal screening it is possible to achieve better diagnosis and prognosis in the case of Rh(D) conditions of alloimmunized pregnancies.

*Key words: ultrasonography, medical imaging, alloimmunization, fetal disorders*

### INTRODUCTION

The impact of different antepartal, intrapartal, and early neonatal risk factors is significant for the course and outcome of a pregnancy, for an early neonatal period and for later growth and development of a child. The case of fetal damage during pregnancy and/or childbirth is a significant problem not only for obstetricians and neonatologists but also for sociologists, family and society as a whole. This situation requires problem identification and risk assessment in order to decrease perinatal (antenatal) morbidity and mortality, and enable normal growth and development of a child.

Alloimmunization indicates the existence of maternal circulating antibodies against fetal erythrocytes [1], related to the response to the existence of extraneous antigen on the foetal erythrocyte membrane. Over many decades, impressive scientific and practical work has been dedicated to the problem of alloimmunization. There are countries, especially those with developed health care systems, where alloimmunization no longer exists. However, in Serbia and its neighbouring Balkan

countries alloimmunization is still present and represents one of the vital problems of perinatal control.

This paper examines the role of ultrasonography in early diagnosis of alloimmunization related disorders. As opposed to alternative procedures, such as amniocentesis or cordocentesis, ultrasound imaging is a non-invasive method, which provides reliable insight into the condition of a fetus.

### HAEMOLYTIC DISEASE OF THE FETUS/NEONATE (HDFN)

In the haemolytic disease defined by Rh(D) [2, 3] alloimmunization contributes significantly to perinatal morbidity and mortality. The haemolytic disease of fetus/neonate (HDFN) is the disease with genetic predisposition and it represents a process of production of IgG anti-D antibodies in blood of an Rh(D) negative pregnant woman that go over into the circulation of Rh(D) positive fetus, being absorbed on D positive erythrocytes or stay free in fetal serum [4-6]. Antibodies absorbed in this way represent haemolysins that destroy erythrocytes. Effective explanation of agglutination, caused by incomplete antibodies only

\* Corresponding author; e-mail: monikaz@verat.net

based on changes in physical and chemical properties of the environment is based on the fact that erythrocytes in suspension have negative charge on the surface. This prevents molecular binding, until charge is released or dielectric properties of suspension are altered. Therefore, electric charge and z-potential enables reaction antigen-antibody and subsequent agglutination of erythrocytes [7-10]. The process can be mild, which does not require specific therapy, but if pronounced it can cause fetal anaemia, hydrops, or even intrauterine fetal death [1, 11]. If the process has started earlier and if it is more intensive, the consequences are more severe. There are two possible mechanisms of Rh(D) alloimmunization: transfusion of incompatible blood (non-obstetric cause) or foetomaternal hemorrhagic (obstetric cause) [12].

HDFN caused by alloimmunization becomes permanently actual condition for multiple reasons: females with already created anti-D antibody become pregnant for multiple times, after immune conditions as termination of pregnancy [13], amniocentesis [14] or in the case of normal delivery the administration of anti-D is often insufficient if foetomaternal hemorrhagic conditions occurred in pregnancy before administration of anti-D immunoglobulin [15].

Prevention and therapy of HDFN requires continuous monitoring in antenatal, intrapartal, postpartal, and neonatal phase as well as in the later childhood. Development of medical sciences in the last decades, in parallel with improved therapeutic and diagnostic procedures has significantly changed the prognosis in HDFN conditions. The most important progress was achieved when direct access to fetal circulation has become possible. Initially, it was achieved using foetoscope, however, ultrasound based techniques have become available soon after that. The latter technique is performed by ultrasonographically guided puncture of umbilical vein at the spot of placental insertion of umbilical cord, known as cordocentesis [16, 17]. First intrauterine intravascular transfusions (IUIVT) [18] were performed during the eighties, and had a great impact on improvement of the fetal condition and its survival. In some cases the survival rate is as high as 90%. IUIVT facilitate the treatment of fetal hydrops and fetal anaemia (*i. e.* stopping of extramedullary erythropoiesis), and thereby the improvement of fetal hypoxia and prevention of intrauterine fetal death [17-19]. This also provides better vital potential for development of the fetus.

Certain clinical aspects of Rh(D) alloimmunization have been recognized for more than a century, however, detailed etiology of disease have been discovered few decades ago which enabled better understanding, diagnosis and treatment of this condition [2, 3]. Attention has been drawn to prevention and therapy, based on the fact that Rh(D) alloimmunization of mother against Rh(D) fetal antigen is preventable by application of adequate quan-

tity of hyperimmune anti-D immunoglobulin [15]. However, in spite of prophylactic treatments and antenatal and postnatal treatments, the outcome of alloimmunized pregnancies is still uncertain.

Clinical manifestation of Rh(D) alloimmunization caused HDFN has been more efficiently recognized in the recent period, due to development of modern techniques for assessment of fetal anomalies. By evaluation of anaemia using ultrasound imaging [20-22] and assessment of the fetus age, as well as by timely application of intrauterine therapy [14, 18], it is possible to improve the prognosis in the childhood [13, 23]. This includes better vital capacity and application of reanimation methods, transfusion [23], and adequate follow up in early childhood. However, further investigation is needed, in order to collect more reliable data about survival rate and further growth and development of the child. Long-term prospective studies for longitudinal follow up are of utmost importance here [24-29] including non-invasive diagnostic methods [7, 30-32].

## MEDICAL ULTRASONOGRAPHY

Ultrasonography is an ultrasound-based diagnostic imaging technique used for visualizing subcutaneous body structures. Ultrasound refers to sound waves at frequencies higher than the range of the human ear, *i. e.* at frequencies greater than about 20 kHz. For medical application, frequencies typically 100 times higher than audible by humans are used (2 to 20 MHz). Ultrasonic waves obey the same basic laws of wave motion as lower frequency sound waves, but they have, however, the following advantages: (a) higher frequency waves have shorter wavelengths; this means that diffraction or bending around an obstacle of given dimensions is correspondingly reduced; it is therefore easier to direct and focus a beam of ultrasound, (b) ultrasonic waves can easily pass through tissue; this means that the entire ultrasound system can be mounted completely externally to the body, *i. e.* it is non-invasive.

The most commonly used devices for ultrasonic transmitters and receivers (usually assembled in one device, called transducer) are piezoelectric sensing elements. The piezoelectric effect is reversible, *i. e.* mechanical energy can be converted into electrical energy and electrical energy into mechanical. The ultrasonic transmitter uses the inverse piezoelectric effect, if a sinusoidal or impulse voltage is applied to the transmitting crystal, then the crystal undergoes a corresponding deformation. This vibration of the crystal is transmitted to the tissue. The frequency of sound, called resonance frequency is equal to the frequency of the driving voltage. For each pulse of ultrasound, a series of echoes are returned as the ultrasound pulse is reflected from objects at a greater or lesser distance. These echoes are received by the receiver and con-

verted to electrical pulses, via the direct piezoelectric effect. The echo is generated at each boundary between two different materials, *i. e.* tissues, or where some inhomogeneity is present in the same tissue.

For measurement of velocity, the Doppler effect is used. Doppler ultrasound is based on the Doppler principle, that ultrasound changes frequency when either the source or the receiver is moving. Doppler-shifted echoes are generated when vessel walls or blood are in motion. In ultrasound scanners, a series of pulses is transmitted to detect movement of blood. Echoes from stationary tissue are the same from pulse to pulse. Echoes from moving objects exhibit slight differences in the time needed for the signal to be returned to the receiver. These differences can be measured as a difference in frequency usually called the Doppler frequency

$$f_d = \frac{2f_t v \cos \theta}{c} \quad (1)$$

where  $f_t$  is the frequency of transmitted ultrasound,  $v$  – the speed of the blood,  $c$  – the speed of ultrasound in tissue, and  $\theta$  – an angle of incidence between the blood flow and the direction of emitted ultrasound pulse. The echoes are then processed to produce either a color flow display or a Doppler sonogram.

## METHODS

Two samples were formed from Rh(D) alloimmunized pregnant patients with and newborns with severe clinical form of Rh(D) alloimmunization. The first sample included 52 newborns in the period 1998-2007 (initial period of IUIVT) while the second one included 16 newborns in the period 1998-2008 (second period of IUIVT, when better pre natal control was achieved). Groups were formed from the patients of the Institute for gynaecology of the Clinical centre of Serbia. The examination IUIVT was performed on these groups of patients and results were compared. Criteria for inclusion patient in the sample were: titre of mother's antibody, ultrasonographic examination of fetus and application of IUIVT [33-36].

There is evidence that in hidrops free foetuses, where risk of Rh(D) alloimmunizations ranges from moderate to promulgated, anaemia can be non invasively diagnosed using ultrasound (Doppler flow) examinations [20-22]. The examination is based on the increased peak value of the systolic ejection in middle cerebral artery of fetal brain. This artery has rapid response to hypoxemia, with the regard to brain oxygen dependence. The effect is readily visible on ultrasound images. Based on animal experiments, positive peak observed in the ultrasound images is related to reduced blood flow due to increased systolic ejection, reduced blood viscosity and increased hematocrit. Systolic ejection peak in the middle cerebral artery is very efficient in detection of anomalies in alloimmunized pregnan-

cies and is a diagnostic method of choice prior cordocentesis. The sensitivity of the method to assessment of anaemia level is up to 100%, with error up to 12% [30, 32, 37]. Therefore, the ultrasound based early diagnosis is a method of choice for early diagnosis of Rh(D) alloimmunizations, with minimal adverse effects.

One of the non-invasive diagnostic methods for early detection of Rh(D) alloimmunization is detection of titre Rh(D) antibodies, as it is exclusively related to the risk of HDFN. The test is preformed in albumin, papain, salty, and Coombs environment. In most pregnancies titre of antibodies in salty and albumin environment is lower than 1:32, while in other environments (papain and Coombs) it is higher than 1:32. This indicates that titre of Rh antibodies in enzyme and Coombs environment is more accurate indicator of the level of immunization of the mother and the condition of fetus during alloimmunized pregnancy.

## RESULTS

Results are presented in tabs. 1 and 2, and figs. 1-4. Levels of titre of antibodies in salty environment, in both control and analyzed groups indicated moderate sensitization in a small group of patients. However, in albumin and in particular Coombs environment, the level of sensitization was significant in all patients ( $p > 0.05$ , DF = 67).

## DISCUSSION AND CONCLUSIONS

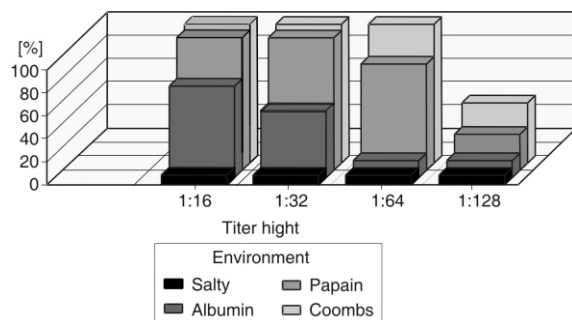
Titre of Rh(D) antibodies in Coombs environment is more relevant indices then titre in albumins and especially in salty environment. Increase of titre in Rh(D) alloimmunized pregnancies indicates that fetal

**Table 1. Antibodies in maternal serum in the analysed group**

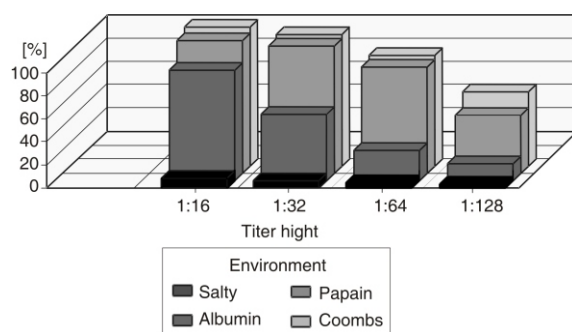
Titre	Environment			
	Salty	Albumin	Papain	Coombs
0	9	–	–	–
1:2	3	1	–	–
1:4	2	1	–	–
1:8	1	1	1	–
1:16	–	4	–	–
1:32	–	7	1	–
1:64	–	–	10	10
1:128	1	1	3	4
1:256	–	1	–	1
1:512	–	–	–	1
1:1024	–	–	1	–
1:2048	–	–	–	–
1:4096	–	–	–	–
Total	16	16	16	16

**Table 2. Antibodies in maternal serum in the control group**

Titre	Environment			
	Salty	Albumin	Papain	Coombs
0	42	–	–	–
1:2	3	–	–	–
1:4	1	1	–	–
1:8	3	7	1	–
1:16	2	14	3	3
1:32	–	20	8	9
1:64	–	4	22	17
1:128	–	3	13	16
1:256	1	3	2	4
1:512	–	–	–	1
1:1024	–	–	1	1
1:2048	–	–	1	1
1:4096	–	–	1	–
Total	52	52	52	52

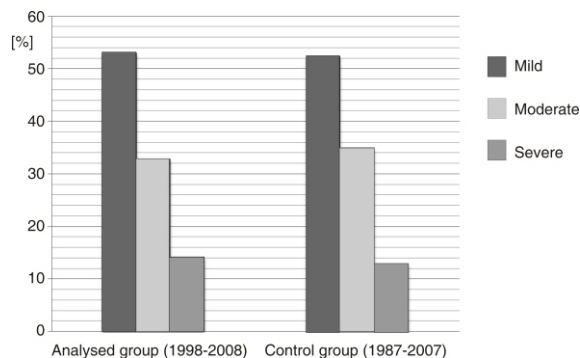


**Figure 1. Antibodies in maternal serum in the analysed group**

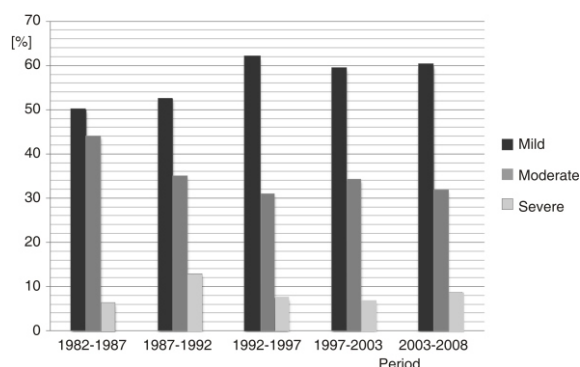


**Figure 2. Antibodies in maternal serum in the control group**

Rh factor is positive. However, the time of first manifestation of Rh antibodies during pregnancy is very significant. Although a repeated test for antibodies in maternal serum is a simple and efficient procedure, it is not precise enough to assess the weight of HDFN. It could be only an auxiliary diagnostic test. Titre Rh an-



**Figure 3. Clinical forms of hemolytic disease in analyzed group in the period 1998-2008 and control group for the period 1987-2007**



**Figure 4. Time dependence of clinical forms of hemolytic disease in newborn for the period 1982-2008**

tibodies in Coombs environment are more relevant in the case of alloimmunized pregnancies.

Invasive diagnostic procedures, such as amniocentesis or cordocentesis, and the early delivery, could lead to an unsatisfactory outcome of the pregnancy. Only an organized treatment of pregnant women with Rh(D) alloimmunization minimizes the possibility of morbidity and mortality. Non-invasive procedures should, therefore, be the methods of choice in prenatal diagnostics.

Anaemia can be non-invasively detected in fetus. Non-invasive detection enrolls antibody titre and flow measurements using Doppler ultrasound. The latter is based on the increase of the peak that corresponds to the systolic ejection in cerebral brain artery of fetus. Middle cerebral artery has rapid response to hypoxemia, as it is oxygen-dependent. Thus, this effect can be seen using ultrasound. Systolic ejection peak speed in middle cerebral artery is important for anaemia detection in the case of Rh(D) alloimmunized pregnancies. Positive peak in ultrasound is based on the fact that blood vessels in the anaemia condition exhibit decrease in flow rate. The reason for this lays in the increased systolic ejection and reduced viscosity when hematocrit is increased.

Goal of antenatal test is the detection of risks for fetus in earliest possible stage of pregnancy in order to correct fetal anaemia. In this way child is born in optimal timing and in good vital conditions. With ultrasound as a method of choice and with prenatal screening, it is possible to achieve better diagnosis and prognosis in the case of Rh(D) conditions of alloimmunized pregnancies. In this way, the use of invasive methods and application of IUIVT is not necessary. As a rule of thumb, diagnosis always starts with less invasive screening tests.

#### ACKNOWLEDGEMENT

The Ministry of Education and Science of the Republic of Serbia supported this work under contract 171007.

#### REFERENCES

- [1] Cvetković, M., Ljubić, A., Fetal Eritroblastosis, Protocol of Feto-Maternal Medicine, Clinical Centre of Serbia (in Serbian), Institute of Gynaecology, Belgrade, Serbia, 2002
- [2] Landsteiner, K., Weiner, A. S., An Agglutinable Factor in Human Blood Recognized by Immune Sera for Rhesus Blood, *Proc Soc Exp Biol Med*, 43 (1940), 1, pp. 223-224
- [3] Levine, P., Katzin, E. M., Burnham, L., Isoimmunization in Pregnancy: Its Possible Bearing Etiology of Erythroblastosis Fetalis, *JAMA*, 116 (1941), 9, pp. 825-827
- [4] Judd, W. J., Westhoff, C. M., Guidelines for Prenatal and Perinatal Immunohematology, American Association of Blood Banks, USA, 2005
- [5] Šulović, V., Plećaš, D., Rh Factor in Pregnancy (in Serbian), Medicinska knjiga, Belgrade, Serbia, 1986
- [6] Jones, R. F., Lopez, K. H., Human Reproductive Biology, 3<sup>rd</sup> ed., Academic Press, USA, 2006
- [7] Hughes-Jones, N. C., *et al.*, Anti-D Concentration in Mother and Child in Hemolytic Disease of the Newborn in Immunology (Eds. W. Luttmann, K. Bratke, M. Kupper, D. Myrtek) Academic Press, USA, 2006
- [8] Jovanović-Srzić, S., *et al.*, Antibodies Detected in Samples from 21730 Pregnant Women, *Immunology*, 19 (2003), 3, pp. 89-92
- [9] Miletić, V., Immunoglobulins and Immunocomplexes (in Serbian), *Pediatrics*, 7 (1992), 4, pp. 343-353
- [10] Abrams, M. E., *et al.*, Hydrops Fetalis: A Retrospective Review of Cases Reported to a Large National Database and Identification of Risk Factors Associated with Death, *Pediatrics*, 120 (2007), 1, pp. 84-89
- [11] Feldman, N., Skoll, A., Sibai, B., The Incidence of Significant Fetomaternal Hemorrhage in Patients Undergoing Cesarean Section, *Am J Obstet Gynecol*, 163 (1990), 3, pp. 855-858
- [12] Chown, B., Bowman, W. D., The Place of Early Delivery in the Prevention of Fetal Death from Erythroblastosis, *Pediatr North Am*, 14 (1958), 4, pp. 279-288
- [13] Liley, A. W., Liquor Amnii Analysis in Management of Pregnancy Complicated by Rhesus Immunization, *Am J Obstet Gynecol*, 82 (1961), 2, pp. 1359-1371
- [14] Bowman, J., Pollock, J., Failures of Rh Immune Globulin Prophylaxis: An Analysis for the Reasons of Such Failures, *Transf Med Rev*, 1 (1987), pp. 101-112
- [15] Daffos, F., Capella-Pavlovsky, M., Forester, F., Fetal Blood Sampling During Pregnancy with Use of a Needle Guided by Ultrasound, *Am J Obstet Gynecol*, 153 (1985), 6, pp. 655-660
- [16] Harman, C. R., *et al.*, Use of Intravascular Transfusion in Treat Hydrops Fetalis in Moribund Fetus, *Can Med Assoc J*, 138 (1988), 9, pp. 827-830
- [17] Liley, A. W., The Development of Idea Fetal Transfusion, *Am J Obstet Gynecol*, 111 (1971), 2, pp. 303-304
- [18] Plećaš, D., Chitkara, U., Berkowitz, G. S., Intrauterine Intravascular Transfusion for Severe Erythroblastosis Fetalis: How Much to Transfuse?, *Obstetrics and Gynecol*, 75 (1990), 6, pp. 965-969
- [19] Chitkara, U., *et al.*, The Role of Sonography in Assessing Severity of Fetal Anemia in Rh- and Kell-Isoimmunized Pregnancies, *Obstet Gynecol*, 71 (1988), 3, pp. 393-398
- [20] Vyas, S., *et al.*, Middle Cerebral Artery Flow Velocity Waveforms in Fetal Hypoxemia, *Br J Obstet Gynecol*, 97 (1990), 9, pp. 797-803
- [21] Pereira, L., Jenkins, T. M., Berghella, V., Conventional Management of Maternal Red Cell Alloimmunization Compared with Management by Doppler Assessment of Middle Cerebral Artery Peak Systolic Velocity, *Am J Obstet Gynecol*, 189 (2003), 4, pp. 1002-1006
- [22] Wallerstein, H., Treatment of Severe Erythroblastosis by Simultaneous Removal and Replacement of Blood of the Newborn, *Science*, 103 (1946), 2680, pp. 583-585
- [23] \*\*\*, Centers for Disease Control and Prevention: Frequently Asked Questions about Newborn Jaundice and Kernicterus, 2008
- [24] Jovičić, S., Oral Communication: Physiology, Psychoacoustics and Perception (in Serbian), Naučna Knjiga, Belgrade, Serbia, 1999
- [25] Brajović, Lj., *et al.*, Hearing and Hearing Damage (in Serbian), Naučna knjiga, Belgrade, Serbia, 1997
- [26] Ratanasiri, T., *et al.*, Incidence, Causes and Pregnancy Outcomes of Hydrops Fetalis at Srinagarind Hospital 1996-2005, a 10-Year Review, *Med Assoc Thai*, 92 (2009), 5, pp. 594-599
- [27] Huang, H. R., *et al.*, Prognostic Factors and Clinical Features in Liveborn Neonates with Hydrops Fetalis, *Am J Perinatol*, 24 (2007), 1, pp. 33-38
- [28] Harper, D. C., Long-Term Neurodevelopmental Outcome and Brain Volume after Treatment for Hydrops Fetalis by in Utero Intravascular Transfusion, *Am J Obstet Gynecol*, 195 (2006), 1, pp. 192-200
- [29] Copel, J. A., *et al.*, Pulsed Doppler Flow-Velocity Waveforms in the Prediction of Fetal Hematocrit of the Severely Isoimmunized Pregnancy, *Am J Obstet Gynecol*, 161 (1988), 2, pp. 341-344
- [30] Economides, D. L., Anti-D Concentrations in Fetal and Maternal Serum and Amniotic Fluid in Rhesus Allo-Immunised Pregnancies, *British Journal of Obstetrics and Gynecology*, 100 (1993), 10, pp. 923-926
- [31] Frigoletto, F. D., *et al.*, Ultrasonographic Fetal Surveillance in the Management of the Isoimmunized Pregnancy, *Engl J Med*, 315 (1986), 7, pp. 430-432
- [32] Saade, G., Noninvasive Testing for Fetal Anemia, *Obstet and Gynecol*, 342 (2000), 1, pp. 52-53
- [33] Doličanin, Č. B., *et al.*, Statistical Treatment of Nuclear Counting Results, *Nucl Technol Radiat*, 26 (2011), 2, pp. 164-170
- [34] Stanković, K., Influence of the Plain-Parallel Electrode Surface Dimensions on the Type A Measurement Uncertainty of GM Counter, *Nucl Technol Radiat*, 26 (2011), 1, pp. 39-44
- [35] Stanković, K., Statistical Analysis of the Characteristics of Some Basic Mass-Produced Passive Electrical

- Circuits Used in Measurements, *Measurement*, 44 (2011), 9, pp. 1713-1722
- [36] Vujisić, M., Stanković, K., Osmokrović, P., A Statistical Analysis of Measurement Results Obtained from Nonlinear Physical Laws, *Applied Mathematical Modeling*, 35 (2011), 7, pp. 3128-3135

- [37] Copel, J. A., Reed, K. L., Doppler Ultrasound in Obstetrics and Gynecology, Raven Press, New York, USA, 1995

Received on February 10, 2012

Accepted on March 12, 2012

---

**Дарко В. ПЛЕЋАШ, Моника М. ЖИВКОВИЋ, Светлана М. ПЕЈОВИЋ**

**НЕИНВАЗИВНА УЛТРАЗВУЧНА ДИЈАГНОСТИКА Rh(D)  
АЛОИМУНИЗОВАНИХ ТРУДНОЋА**

Неинвазивно ултрасонографско снимање систоличког ејекционог пика у средњој церебралној артерији је веома ефикасан метод детекције аномалије код алоимунизованих трудноћа и представља најпожељнију дијагностичку процедуру пре кордоцентезе. Ова метода примењује се у комбинацији са детектовањем титра Rh(D) антитела. У овој студији тестиране су две групе пацијенткиња, уз поређење добијених резултата. Први узорак састојао се од 52 новорођенчади из периода 1998-2007 (иницијални период интраутералне интраваскуларне трансфузије – IUIVT), док је други укључивао 16 новорођенчади из периода 1998-2008 (други период IUIVT, када је постигана боља пренатална контрола). Нивои титра антитела у сланој средини, код контролне као и код анализираних групе, указали су на умерену осетљивост код малог броја пацијенткиња. С друге стране, у албуминској, а поготово у Кумбсовој (Coombs) средини, ниво сензибилизације је био знатан код свих пацијенткиња ( $p > 0.05$ ;  $DF = 67$ ). Наша анализа показује да је применом ултразвука и уз пренатално праћење могуће постићи боље дијагностичке и прогностичке резултате код Rh(D) стања алоимунизованих трудноћа.

*Кључне речи: ултрасонографија, медицинско сликање, алоимунизација, болести фејџуса*